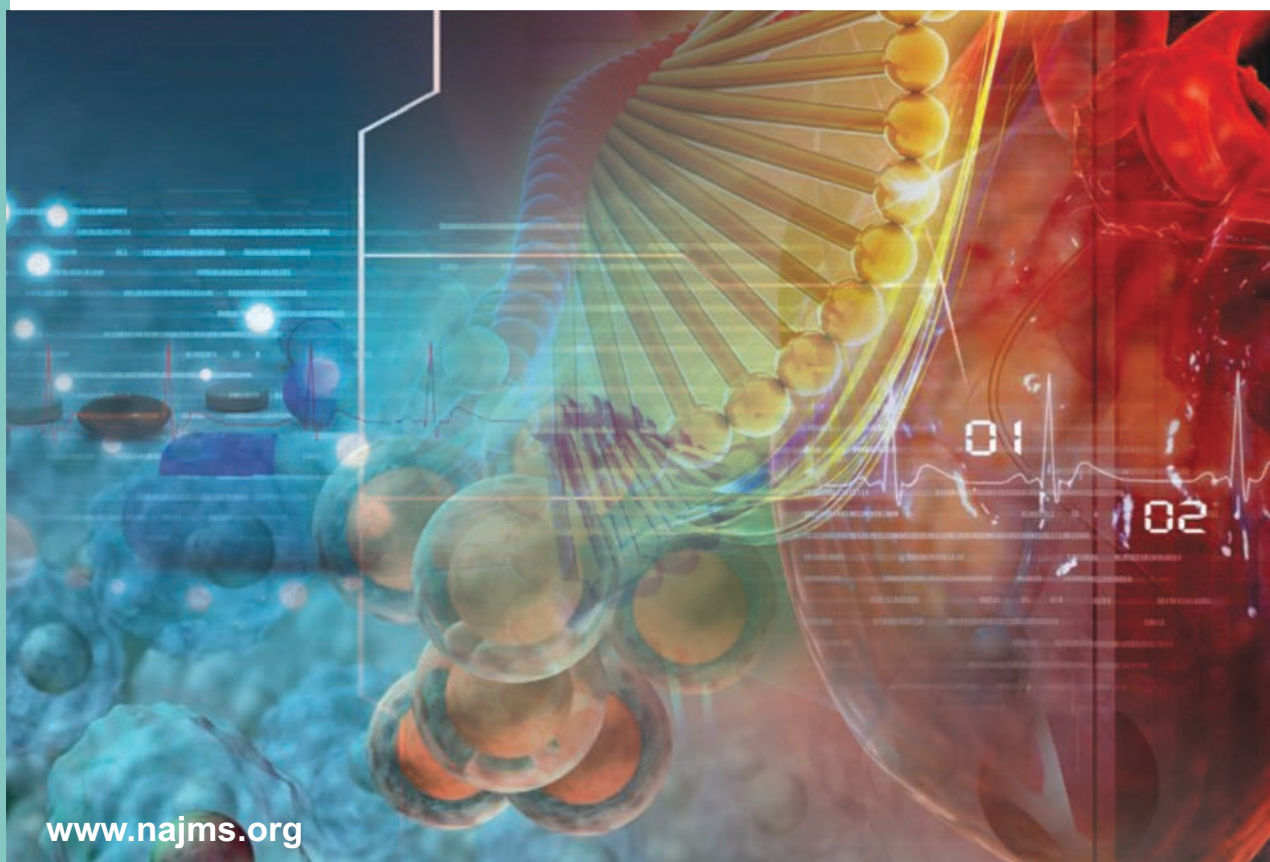


North American Journal of Medical Sciences



www.najms.org

Volume 7, Issue 1, January 2015

Chronic Plantar Fasciitis is Mediated by Local Hemodynamics: Implications for Emerging Therapies

Larry E. Miller, Daniel L. Latt¹

Miller Scientific Consulting, Inc., Asheville, North Carolina, ¹Department of Orthopaedic Surgery, University of Arizona, Tucson, Arizona, United States

Abstract

Plantar fasciitis (PF) is a common, disabling condition affecting millions of patients each year. With early diagnosis and timely application of traditional nonsurgical treatments, symptoms generally resolve over time. However, despite adequate treatment, 20% of patients will experience persistent symptoms. In these patients, minimally invasive therapies that augment local hemodynamics to initiate a regenerative tissue-healing cascade have the greatest potential to resolve long-standing symptoms. We performed a narrative review based on a best evidence evaluation of manuscripts published in Medline-indexed journals to determine the mechanisms involved in soft tissue injury and healing. This evaluation also highlights emerging minimally invasive therapies that exploit these mechanisms in recalcitrant PF.

Keywords: Heel pain, Hemodynamics, Minimally invasive, Plantar fasciitis

Address for correspondence: Dr. Larry E. Miller, Miller Scientific Consulting, Inc., 1854 Hendersonville Road, # 231, Asheville, North Carolina - 28803, United States. E-mail: larry@millerscientific.com

Introduction

Plantar heel pain is the most common reason for visits to foot and ankle specialists, accounting for 1-2 million annual visits in the US alone.^[1,2] Plantar fasciitis (PF) is the predominant diagnosis,^[3] a condition characterized by degeneration of the plantar fascia and perifascial structures with isolated inferior heel pain, particularly with the first steps of the day and after prolonged sitting.^[4] Approximately 1 in 10 people will be diagnosed with PF during their lifetime,^[5] with women aged 40-60 years most commonly affected.^[6] Risk factors include limited ankle dorsiflexion, flatfoot deformity, obesity, and prolonged work-or activity-related weight bearing.^[6-8] PF negatively impacts health-related quality of life^[9] and is responsible for a significant societal economic

burden, with almost 300 million dollars annually spent on physician visits and treatments.^[10]

With early diagnosis and timely application of traditional nonsurgical treatments such as activity modification, gastrocnemius and plantar fascia-specific stretching, anti-inflammatory medications, and/or shoe inserts, the prognosis is favorable with approximately 80% of patients achieving symptom resolution within 1 year.^[11-13] Symptoms may persist in some patients despite increasingly aggressive therapies such as corticosteroid injections, night splints, or cast/boot immobilization. Since the etiology of these recalcitrant cases is controversial and likely multifactorial, numerous therapies with various mechanisms of action have been attempted, although none have an ideal efficacy and safety profile. Conventional treatments for chronic PF may be misdirected, while therapies which augment local hemodynamics, thereby initiating a regenerative tissue healing cascade, have the greatest potential to resolve long-standing symptoms.

We performed a narrative review based on a best evidence evaluation of manuscripts published in Medline-indexed journals to determine the mechanisms

Access this article online

Quick Response Code:



Website:
www.najms.org

DOI:
10.4103/1947-2714.150080

involved in soft tissue injury and healing. This evaluation also highlights emerging minimally invasive therapies that exploit these mechanisms in recalcitrant PF.

Mechanism of plantar fascia injury

The plantar fascia connects the medial calcaneal tuberosity to the proximal aspect of the phalanges, plays a major role in supporting the medial longitudinal arch, and aids in dynamic shock absorption.^[14] The term plantar fascia is actually a misnomer since this structure is not a fascial layer, but a tendinous aponeurosis that shares histological and mechanical traits with tendons and ligaments.^[15] Therefore, it is relevant to compare the etiology, pathophysiology, and treatment of PF to the analogous processes which occur in degenerative diseases of other tendons (tendinosis).

It is generally believed that PF is initiated by excessive tensile strain within the fascia during repetitive loading producing microscopic tears and an acute inflammatory response. Macrophages, lymphocytes, and plasma cells infiltrate the calcaneal entheses causing tissue destruction. If the insult persists, and the reparative process is unable to keep up with the ongoing mechanical demands, then the attempted healing instead produces immature vascularization and fibrosis.^[16] Tissue degeneration (fasciosis), rather than inflammation, then becomes the cardinal pathologic feature. A number of studies have analyzed tissue samples from patients with chronic PF and have found no evidence of inflammation.^[16-19] Similarly, histological analyses of surgical biopsies of tendons affected by “tendonitis” have revealed no evidence of inflammatory cell invasion.^[20-24]

Plantar fascia thickening^[25] and loss of normal tissue elasticity^[26] play an important role in the genesis of persistent inferior heel pain. There is a fivefold increase in the mechanical stiffness of the plantar fascia in pathologic feet compared with healthy ones. This increased stiffness results in higher tissue hydrostatic pressure within the plantar tissues during loading, consequently acting on the external surface of blood vessels to reduce the flow cross-section area local blood supply.^[27] This cascade of events has been hypothesized to cause tissue necrosis and replacement with undifferentiated scar tissue and is the presumed reason for lack of response to traditional nonsurgical therapies.^[28]

Once damaged, the biological and biomechanical properties of connective tissue are never completely restored. Healing times in chronic tendinopathies are often prolonged since local blood flow is only about one-third of that delivered to the muscles.^[29] Moreover, augmenting the local blood flow has been shown to hasten regeneration of damaged connective tissue.^[30] The

proximal plantar fascia is relatively hypovascular, as it is perfused by only a few vessels with none at its insertion onto the calcaneus – the point of maximal tenderness in chronic PF. These findings form the rationale for our hypothesis that exogenous stimulation of local circulation via increasing blood flow, angiogenesis, or by direct application of blood-derived products may hasten healing with chronic PF.

Treatment decision-making

Treatment decision-making for chronic PF is challenging given that there are dozens of available treatment options with no clear gold standard. Unfortunately, the effectiveness of continued conservative treatment for inferior heel pain diminishes if symptoms have not resolved with 3-6 months of standard treatment. In these cases, patients must consider more invasive options to achieve satisfactory symptom relief. Treatment decision-making is further complicated by the lack of evidence for emerging therapies.

Given the compelling evidence that chronic subcalcaneal heel pain stems from a degenerative process, it is imperative that the rationale for use of currently available therapies be reevaluated. For example, corticosteroid injections are extensively utilized in patients with chronic inferior heel pain. However, given the absence of a measurable inflammatory response, the utility of corticosteroid injections appears to be misdirected and may partially explain their limited effectiveness in recalcitrant cases.

The reluctance to adopt noninvasive or minimally invasive therapies for chronic PF was evident from a survey of 84 orthopedic surgeons who were asked to provide treatment recommendations for a hypothetical patient presenting with PF resistant to 10 months of nonoperative management.^[31] Over 50% of surgeons chose surgery (gastrocnemius recession or open plantar fasciotomy) as their preferred next step in management despite only moderate patient success rates, extended recovery times, and potential complications such as nerve injury, plantar fascia rupture, medial longitudinal arch destabilization, and altered loading patterns.^[32-38] Consideration of emerging treatments focused on augmenting local hemodynamics, which is hypothesized to play a major role in lingering PF cases, is warranted to fill the therapeutic gap between ineffective conservative care and invasive surgical options in the patient with chronic PF refractory to conventional therapy.

Minimally invasive therapies for chronic PF

Given the growing evidence for the role of local hemodynamics in chronic PF, therapies intended to stimulate angiogenesis and/or improve local circulation

have recently been explored with promising results. Tendinosis forms as an imbalance between the demands that are placed on a tendon and its ability to remodel. Thus, the key to successful treatment may hinge on augmenting local circulation, which may revert a chronic lesion to an acute lesion by stimulating the inflammatory phase of the healing cascade.

Extracorporeal shockwave therapy

Extracorporeal shockwave therapy is a minimally invasive treatment for recalcitrant PF. The mechanism of action remains unknown, although the current opinion is that focused application of shock waves to injured soft tissue disrupts scar tissue and induces revascularization, releases local growth factors, and recruits stem cells; all of which enhance the intrinsic healing process.^[39] Success rates have ranged from 34 to 88% in well-selected patients.^[40] A meta-analysis of randomized placebo-controlled trials demonstrated that the odds of achieving clinical success was more than twice as high with high-energy extracorporeal shockwave therapy vs sham therapy through 12 weeks.^[41] Through 6-12 months follow-up, extracorporeal shockwave therapy yields similar improvements in foot pain and function compared to autologous condition plasma^[42] and endoscopic plantar fasciotomy,^[43] and superior improvements versus conservative care in patients with chronic PF.^[42] However, over the long-term, extracorporeal shockwave therapy has been shown to be no more effective than plantar fascia-specific stretching^[44] and some studies have reported marginal improvement above that of sham treatment.^[45] Consequently, extracorporeal shockwave therapy remains a controversial therapy for recalcitrant PF. Diverse treatment protocols are thought to confound patient outcomes including different therapeutic doses, applicator positions, and use of local anesthesia.^[46-48]

Radiofrequency microtenotomy

The radiofrequency microtenotomy technique has been applied to chronic tendinopathies for over a decade with promising results. Radiofrequency microtenotomy stimulates angiogenesis in the avascular, fibrotic fascia, which promotes secretion of fibroblastic growth factor, vascular endothelial growth factor, and vascular cells. Histologic evaluation of treated tendons shows an early inflammatory response, with extensive proliferation of vascular cells and new blood vessel formation by 28 days.^[49] Patients with chronic isolated Achilles tendinopathy refractory to nonoperative treatment rated their clinical outcome with radiofrequency microtenotomy as good or excellent with an average of 2.5 years follow-up.^[50] Several case series have reported promising outcomes in recalcitrant PF,^[51-56] with the open method more efficacious than the percutaneous technique.^[56] No comparative studies have been

performed to date with radiofrequency microtenotomy and follow-up data is limited to 1 year or less in all studies.

Platelet-rich plasma (PRP) injections

PRP is an autologous biological blood-derived product that contains high concentrations of platelet-derived growth factors. When used for the treatment of PF, 20-30 ml of the patient's blood is drawn and spun down, which yields 3-5 ml of platelet-rich substrate. Soft tissue healing is thought to be stimulated via enhanced fibroblast migration and proliferation, up regulated vascularization, and increased collagen deposition.^[57,58] In one case series of 50 patients with refractory PF injected with PRP, mean pain severity improvement was 45% at 6 months with almost two in three patients reporting satisfaction with the treatment.^[59] Other case series with no more than 1-year follow-up have reported similar outcomes with patient satisfaction rates of 79-96%.^[60,61] To date, no controlled studies of PRP in chronic PF have been performed.

Micromobile compression (MMC)

MMC is a noninvasive technology that augments circulation through the deep veins of the leg via cyclic pressure pulses to the plantar venous plexus. The platform for the MMC is an orthotic that provides cyclic compression to the arch of the foot when the user is non-weight bearing. Dohm *et al.*,^[62] reported that MMC augmented blood flow velocity 12-fold above resting levels in the posterior tibial vein and fourfold above resting levels in the popliteal vein of healthy adults. Charles and colleagues^[63] compared MMC and below-knee graduated compression stockings on peak venous velocity at the popliteal vein. MMC yielded a four fold increase in peak venous velocity vs no change for compression stockings. It was subsequently hypothesized that since compression of the deep venous plexus increases perfusion through the plantar fascial microvasculature, this technology may have potential in the treatment of patients with PF.

MMC for the treatment of PF has been attempted so far in one patient. A 39-year-old otherwise healthy woman (body mass index of 23 kg/m²) had a 2-year history of inferior heel pain. The patient complained of moderate/severe inferior heel pain and stiffness on the first steps of the morning, after prolonged sitting, and with ambulation > 30 min. She rated her pain as 8/10 with ambulation. She had tried activity modification, anti-inflammatory medications, physical therapy, orthotics, soft tissue manipulation, night splint, and multiple corticosteroid injections all without relief. Physical examination revealed a tight heel cord with dorsiflexion limited to neutral with the knee extended

and tenderness to palpation at the insertion of the PF. Plain X-rays demonstrated a small plantar heel spur but no arthritis. Magnetic resonance imaging (MRI) was used to exclude other potential causative factors such as calcaneal stress fracture and tumor. Ultrasound examination revealed thickening of the plantar fascia (7 mm) and mild retrocalcaneal bursitis. MMC was applied for 2-3 h/day, 5-6 days/week, for 2 months. No concomitant therapies were administered during this period. Pain severity during ambulation decreased to 6 over the first week, 4 at 1 month, and 4 at 2 months. During the 2-month treatment period, the patient was able to gradually increase her physical activity from walking 2-4 miles, two to three times per week to walking/jogging 3-5 miles, four to five times per week. She did not experience discomfort or side effects from the use of MMC. A randomized controlled study of conservative care, with or without MMC, is planned to begin enrollment in early 2015 to further evaluate the potential of MMC for PF.

Conclusion

PF is a misunderstood condition with little consensus regarding optimal treatment practices. Chronic PF is not associated with inflammation, but instead with tissue degeneration. Classical treatments including stretching, shoe inserts, and anti-inflammatory medications are effective in 80% of cases. Refractory cases have traditionally been treated with surgery although iatrogenic risks prevent widespread utilization. The emerging minimally invasive therapies have the potential to speed recovery in patients with chronic PF and may serve as an alternative to surgery for patients refractory to traditional nonsurgical treatments. Research efforts should thus concentrate on these emerging minimally invasive therapies that promote tissue regeneration by augmenting local hemodynamics.

References

- Riddle DL, Schappert SM. Volume of ambulatory care visits and patterns of care for patients diagnosed with plantar fasciitis: A national study of medical doctors. *Foot Ankle Int* 2004;25:303-10.
- Pfeffer G, Bacchetti P, Deland J, Lewis A, Anderson R, Davis W, *et al.* Comparison of custom and prefabricated orthoses in the initial treatment of proximal plantar fasciitis. *Foot Ankle Int* 1999;20:214-21.
- Yi TL, Lee GE, Seo IS, Huh WS, Yoon TH, Kim BR. Clinical characteristics of the causes of plantar heel pain. *Ann Rehabil Med* 2011;35:507-13.
- Lynch DM, Goforth WP, Martin JE, Odom RD, Preece CK, Kotter MW. Conservative treatment of plantar fasciitis. A prospective study. *J Am Podiatr Med Assoc* 1998;88:375-80.
- DeMaio M, Paine R, Mangine RE, Drez D Jr. Plantar fasciitis. *Orthopedics* 1993;16:1153-63.
- Riddle DL, Pulisic M, Pidcoe P, Johnson RE. Risk factors for Plantar fasciitis: A matched case-control study. *J Bone Joint Surg Am* 2003;85-A:872-7.
- Pohl MB, Hamill J, Davis IS. Biomechanical and anatomic factors associated with a history of plantar fasciitis in female runners. *Clin J Sport Med* 2009;19:372-6.
- Bolgia LA, Malone TR. Plantar fasciitis and the windlass mechanism: A biomechanical link to clinical practice. *J Athl Train* 2004;39:77-82.
- Irving DB, Cook JL, Young MA, Menz HB. Impact of chronic plantar heel pain on health-related quality of life. *J Am Podiatr Med Assoc* 2008;98:283-9.
- Tong KB, Furia J. Economic burden of plantar fasciitis treatment in the United States. *Am J Orthop (Belle Mead NJ)* 2010;39:227-31.
- Martin RL, Irrgang JJ, Conti SF. Outcome study of subjects with insertional plantar fasciitis. *Foot Ankle Int* 1998;19: 803-11.
- Wolgin M, Cook C, Graham C, Mauldin D. Conservative treatment of plantar heel pain: Long-term follow-up. *Foot Ankle Int* 1994;15:97-102.
- Davis PF, Severud E, Baxter DE. Painful heel syndrome: Results of nonoperative treatment. *Foot Ankle Int* 1994;15: 531-5.
- Khan KM, Cook JL, Taunton JE, Bonar F. Overuse tendinosis, not tendinitis part 1: A new paradigm for a difficult clinical problem. *Phys Sportsmed* 2000;28:38-48.
- Boabighi A, Kuhlmann JN, Luboinski J, Landjerit B. Aponeuroses and superficial fascia. Mechanical and structural properties. *Bull Assoc Anat (Nancy)* 1993;77:3-7.
- Lemont H, Ammirati KM, Usen N. Plantar fasciitis: A degenerative process (fasciosis) without inflammation. *J Am Podiatr Med Assoc* 2003;93:234-7.
- Schepesis AA, Leach RE, Gorzyca J. Plantar fasciitis. Etiology, treatment, surgical results, and review of the literature. *Clin Orthop Relat Res* 1991;185-96.
- Tountas AA, Fornasier VL. Operative treatment of subcalcaneal pain. *Clin Orthop Relat Res* 1996;170-8.
- Snider MP, Clancy WG, McBeath AA. Plantar fascia release for chronic plantar fasciitis in runners. *Am J Sports Med* 1983;11:215-9.
- Fukuda, H, Hamada K, Yamanaka K. Pathology and pathogenesis of bursal-side rotator cuff tears viewed from en bloc histologic sections. *Clin Orthop Relat Res* 1990;75-80.
- Jozsa L, Reffy A, Kannus P, Demel S, Elek E. Pathological alterations in human tendons. *Arch Orthop Trauma Surg* 1990;110:15-21.
- Kannus P, Jozsa L. Histopathological changes preceding spontaneous rupture of a tendon. A controlled study of 891 patients. *J Bone Joint Surg Am* 1991;73:1507-25.
- Chard MD, Cawston TE, Riley GP, Gresham GA, Hazleman BL. Rotator cuff degeneration and lateral epicondylitis: A comparative histological study. *Ann Rheum Dis* 1994;53:30-4.
- Astrom M, Rausing A. Chronic achilles tendinopathy. A survey of surgical and histopathologic findings. *Clin Orthop Relat Res* 1995;151-64.
- Mahowald S, Legge BS, Grady JF. The correlation between plantar fascia thickness and symptoms of plantar fasciitis. *J Am Podiatr Med Assoc* 2011;101:385-9.
- Sahin N, Ozturk A, Atici T. Foot mobility and plantar fascia elasticity in patients with plantar fasciitis. *Acta Orthop Traumatol Turc* 2010;44:385-91.
- Mithraratne K, Ho H, Hunter PJ, Fernandez JW. Mechanics of the foot Part 2: A coupled solid-fluid model to investigate

- blood transport in the pathologic foot. *Int J Numer Method Biomed Eng* 2012;28:1071-81.
28. Peacock EE Jr. Fundamental aspects of wound healing relating to the restoration of gliding function after tendon repair. *Surg Gynecol Obstet* 1964;119:241-50.
 29. Benjamin M, Ralphs JR. Tendons and ligaments – an overview. *Histol Histopathol* 1997;12:1135-44.
 30. Kajikawa Y, Morihara T, Sakamoto H, Matsuda K, Oshima Y, Yoshida A, *et al.* Platelet-rich plasma enhances the initial mobilization of circulation-derived cells for tendon healing. *J Cell Physiol* 2008;215:837-45.
 31. DiGiovanni BF, Moore AM, Zlotnicki JP, Pinney SJ. Preferred management of recalcitrant plantar fasciitis among orthopaedic foot and ankle surgeons. *Foot Ankle Int* 2012;33:507-12.
 32. Davies MS, Weiss GA, Saxby TS. Plantar fasciitis: How successful is surgical intervention? *Foot Ankle Int* 1999;20:803-7.
 33. Tweed JL, Barnes MR, Allen MJ. An evaluation of the long-term effects of total plantar fasciotomy – A preliminary study. *Foot (Edinb)* 2009;19:75-9.
 34. Tweed JL, Barnes MR, Allen MJ, Campbell JA. Biomechanical consequences of total plantar fasciotomy: A review of the literature. *J Am Pediatr Med Assoc* 2009;99:422-30.
 35. Cheung JT, An KN, Zhang M. Consequences of partial and total plantar fascia release: A finite element study. *Foot Ankle Int* 2006;27:125-32.
 36. Ward ED, Smith KM, Cocheba JR, Patterson PE, Phillips RD. 2003 William J. Stickel Gold Award. *In vivo* forces in the plantar fascia during the stance phase of gait: Sequential release of the plantar fascia. *J Am Pediatr Med Assoc* 2003;93:429-42.
 37. Crary JL, Hollis JM, Manoli A 2nd. The effect of plantar fascia release on strain in the spring and long plantar ligaments. *Foot Ankle Int* 2003;24:245-50.
 38. Brugh AM, Fallat LM, Savoy-Moore RT. Lateral column symptomatology following plantar fascial release: A prospective study. *J Foot Ankle Surg* 2002;41:365-71.
 39. Thiel M. Application of shock waves in medicine. *Clin Orthop Relat Res* 2001;18-21.
 40. Wang CJ. Extracorporeal shockwave therapy in musculoskeletal disorders. *J Orthop Surg Res* 2012;7:11.
 41. Zhiyun L, Tao J, Zengwu S. Meta-analysis of high-energy extracorporeal shock wave therapy in recalcitrant plantar fasciitis. *Swiss Med Wkly* 2013;143:w13825.
 42. Chew KT, Leong D, Lin CY, Lim KK, Tan B. Comparison of autologous conditioned plasma injection, extracorporeal shockwave therapy, and conventional treatment for plantar fasciitis: A randomized trial. *PM R* 2013;5:1035-43.
 43. Radwan YA, Mansour AM, Badawy WS. Resistant plantar fasciopathy: Shock wave versus endoscopic plantar fascial release. *Int Orthop* 2012;36:2147-56.
 44. Rompe JD, Cacchio A, Weil L Jr, Furia JP, Haist J, Reiners V, *et al.* Plantar fascia-specific stretching versus radial shock-wave therapy as initial treatment of plantar fasciopathy. *J Bone Joint Surg Am* 2010;92:2514-22.
 45. Aqil A, Siddiqui MR, Solan M, Redfern DJ, Gulati V, Cobb JP. Extracorporeal shock wave therapy is effective in treating chronic plantar fasciitis: A meta-analysis of RCTs. *Clin Orthop Relat Res* 2013;471:3645-52.
 46. Lee SJ, Kang JH, Kim JY, Kim JH, Yoon SR, Jung KI. Dose-related effect of extracorporeal shock wave therapy for plantar fasciitis. *Ann Rehabil Med* 2013;37:379-88.
 47. Dorotka R, Sabeti M, Jimenez-Boj E, Goll A, Schubert S, Trieb K. Location modalities for focused extracorporeal shock wave application in the treatment of chronic plantar fasciitis. *Foot Ankle Int* 2006;27:943-7.
 48. Rompe JD, Meurer A, Nafe B, Hofmann A, Gerdesmeyer L. Repetitive low-energy shock wave application without local anesthesia is more efficient than repetitive low-energy shock wave application with local anesthesia in the treatment of chronic plantar fasciitis. *J Orthop Res* 2005;23:931-41.
 49. Harwood R, Bowden K, Amiel M, Tasto J, Amiel D. Structural and angiogenic response to bipolar radiofrequency treatment of normal rabbit Achilles tendon: A potential application to the treatment of tendinosis. *Trans Orthop Res Soc* 2003;28:819.
 50. Sarimo J, Orava S. Fascial incision and adhesiolysis combined with radiofrequency microtenotomy in treatment of chronic midportion Achilles tendinopathy. *Scand J Surg* 2011;100:125-8.
 51. Sorensen MD, Hyer CF, Philbin TM. Percutaneous bipolar radiofrequency microdebridement for recalcitrant proximal plantar fasciosis. *J Foot Ankle Surg* 2011;50:165-70.
 52. Weil L Jr, Glover JP, Weil LS Sr. A new minimally invasive technique for treating plantar fasciosis using bipolar radiofrequency: A prospective analysis. *Foot Ankle Spec* 2008;1:13-8.
 53. Sollitto RJ, Plotkin EL, Klein PG, Mullin P. Early clinical results of the use of radiofrequency lesioning in the treatment of plantar fasciitis. *J Foot Ankle Surg* 1997;36:215-9.
 54. Sean NY, Singh I, Wai CK. Radiofrequency microtenotomy for the treatment of plantar fasciitis shows good early results. *Foot Ankle Surg* 2010;16:174-7.
 55. Hormozi J, Lee S, Hong DK. Minimal invasive percutaneous bipolar radiofrequency for plantar fasciopathy: A retrospective study. *J Foot Ankle Surg* 2011;50:283-6.
 56. Tay KS, Ng YC, Singh IR, Chong KW. Open technique is more effective than percutaneous technique for TOPAZ radiofrequency coblation for plantar fasciitis. *Foot Ankle Surg* 2012;18:287-92.
 57. Molloy T, Wang Y, Murrell G. The roles of growth factors in tendon and ligament healing. *Sports Med* 2003;33:381-94.
 58. Foster TE, Puskas BL, Mandelbaum BR, Gerhardt MB, Rodeo SA. Platelet-rich plasma: From basic science to clinical applications. *Am J Sports Med* 2009;37:2259-72.
 59. Kumar V, Millar T, Murphy PN, Clough T. The treatment of intractable plantar fasciitis with platelet-rich plasma injection. *Foot (Edinb)* 2013;23:74-7.
 60. Martinelli N, Marinozzi A, Carni S, Trovato U, Bianchi A, Denaro V. Platelet-rich plasma injections for chronic plantar fasciitis. *Int Orthop* 2013;37:839-42.
 61. Ragab EM, Othman AM. Platelets rich plasma for treatment of chronic plantar fasciitis. *Arch Orthop Trauma Surg* 2012;132:1065-70.
 62. Dohm M, Williams KM, Novotny T. Micro-mobile foot compression device compared with pneumatic compression device. *Clin Orthop Relat Res* 2011;469:1692-700.
 63. Charles T, Mackintosh S, Fingleton J, Braithwaite I, Weatherall M, Beasley R. Efficacy of micromobile foot compression device in increasing lower limb venous blood flow. *Int J Vasc Med* 2013;2013:948769.

How to cite this article: Miller LE, Latt DL. Chronic plantar fasciitis is mediated by local hemodynamics: Implications for emerging therapies. *North Am J Med Sci* 2015;7:1-5.

Source of Support: Nil. **Conflict of Interest:** None declared.